

TINEA CORPORIS RESOLVED BY HOMOEOPATHY IN LM POTENCY: A CASE REPORT

Arun S. Raj* and M. Murugan

*Department of Organon of Medicine and Homoeopathic Philosophy, Sarada Krishna
Homoeopathic Medical College, Kulasekharam, Kanniyakumari District, Tamilnadu.*

ABSTRACT

Ringworm or Tinea or Dermatophytosis, are the most commonly widespread superficially spreading fungal infections seen throughout the world with high significance in developing countries like India, with a higher prevalence of tinea corporis. The Dermatophytes are responsible to cause a variety of skin lesions by infecting skin, hairs nails and body. These organisms metabolize the fibrous protein keratin and cause a range of pathologic clinical presentations, including tinea corporis, tinea pedis, tinea cruris, etc. The recent prevalence of dermatophytosis in India ranges from 36.6 to 78.4%. Here presenting an individual case report in my clinics of a 10 years young male child treated with Graphitis 0/3 in LM Potency in weekly three doses in alternate days, have shown marked improvement in the reduction of the lesion within 2 months.

KEYWORDS: Homoeopathy, Tinea Corporis, Graphitis, LM Potency

* Corresponding Author E-mail: arun.anjanaya@gmail.com

INTRODUCTION

Tinea corporis is common worldwide spreading exceeding disease. Dermatophytes are the most prevalent agents of superficial fungal infections. Excessive heat, high relative humidity, and fitted clothing have correlations to more severe and frequent disease. Specific populations can also be more predisposed to tinea corporis; for example, children. Tinea capitis and tinea corporis are the most common dermatophytic infections in prepubertal children. Children are also more likely to contract zoophilic infections. Zoophilic infections get transmitted via contact with animals such as cats and dogs.¹ These are usually painless and superficial, these fungi can behave in an invasive manner, causing deeper and disseminated infection and should not be neglected. The lesions may become widespread and may have significant negative social, psychological, and occupational health effects, and can compromise the quality of life significantly.²

Another vulnerable population includes patients with compromised immune systems. The immunocompromised patients also have an increased prevalence in developing Majocchi granuloma, a type of tinea corporis folliculitis that invades the deep dermal layers in contrast to the more superficial traditional tinea corporis.²

All people do not have equal susceptibility to fungal infection, and there are familial and genetic predispositions possibly mediated by specific defects in innate and adaptive immunity. Patients with low defense beta 4 may demonstrate a predisposition to all dermatophytes. Some other predisposing factors include underlying diseases such as diabetes mellitus, lymphomas, immunocompromised status, Cushing syndrome, excess sweating, or old age. The currently held view is that a cell-mediated immune response is responsible for the control of dermatophytosis.³ This case was effectively treated with Graphitis in Lm Potency in weekly three doses, used in alternate morning for 8 weeks.

MATERIALS AND METHODS

Case Presentation

Patient was a 10 years young boy with the complaints of skin eruptions especially in the abdomen – right side with two lesions for 1month. Lesions with round shaped, due to itching, scratching present with peeling of skin with shiny dry scales and after there was redness and everted margin. Itching aggravates in evening and night and ameliorates in hot application. The patient complaints starts before 4 months with itching first occur with redness of skin, then eruption occurs with increase itching. Took allopathic treatment relief occurs, while stop the medicine lesion again reappears. So patient is willing to take homoeopathic treatment.

Patients had a history of typhoid fever which is treated with allopathic medication. Relief occurs. Physical generals of the patient with decreased appetite and increased thirst of hot food and water. Sleep is decreased due to the continuous itching with profuse sweat over the whole body. Patient is mentally active with desires company and worried about his studies. Increase irritability with weeping disposition, restless about his complaints. He is very anxious to external things. Patient has aversion to covering with desires fanning. Patient is highly anemic.

The systemic examination of the patient reveals that skin of the patient with white circular patches over the right side of abdomen with everted margin. Two lesions. Shape round edges raised over the abdomen with scaling. Characteristic of eruption is scaly that grows outwards with borders and thickened in between with intense itching++ and burning with no local rise of temperature or tenderness

Homoeopathic Analysis

Patient was treated as whole by considering similimum by constructing a symptom totality by considering his mental, physical and particular symptoms as shown in the table 1 and then repertorise the totality and make the rubrics as shown in table 2. After examining the Repertorial result first prescription is done. Repertorisation chart is shown in figure 1.

Homoeopathic Intervention

The patient was treated and follows up with systemic manner by homoeopathic medicines that have been shown in the table 3 (follow up). The medicines were selected according to the present totality of symptoms. The periodic follow up were done through frequent intervals.

Table 1. Symptoms Evaluation and Totality Based on First Day for the First Prescription

Mental	Physical	Particular
Active child	Appetite decreased	Eruptions, on the right side of abdomen
Desires company	Thirst – Increased (hot water)	Itching with scratching present with peeling of skin with shiny dry scales and after there was redness and everted margin
Restless about his complaints	Sleep - Decreased due to itching.	Itching
Worried about studies	Sweat – profuse over the whole body	< evening
Anxious to external things	Desire fish.	< night
Increase irritability	Desire cold drinks	> hot application
Weeping disposition	Desire sweets	Itching
	Desires fanning	White scaly dry patches
	Aversion to covering.	Peeling of skin
	Desires chocolate.	

Table 2. Rearranging totality for the final selected remedy

S. No	Repertorial totality	S. No	Repertorial result
1	Mind – company – desires for	1	ARS : 24/10
2	Mind – Restlessness, nervousness	2	MERC: 18/9
3	Mind – Weeping, tearful mood etc	3	MEZ: 18/9
4	Skin – Eruptions – whitish	4	GRAPH: 16/9
5	Skin – Eruptions – dry	5	LYC: 18/8
6	Skin – Eruptions – itching	6	PHOS: 16/8
7	Skin – Eruptions – itching – evening	7	STAPH: 15/8

8	Skin – Eruptions – itching – night	8	ZINC: 11/8
9	Skin – Eruptions – scratching, after	9	THUJA: 9/8
10	Skin – Eruptions – red, margin	10	SULPH : 18/7
11	Skin – Eruptions – scaly – white itching – evening		

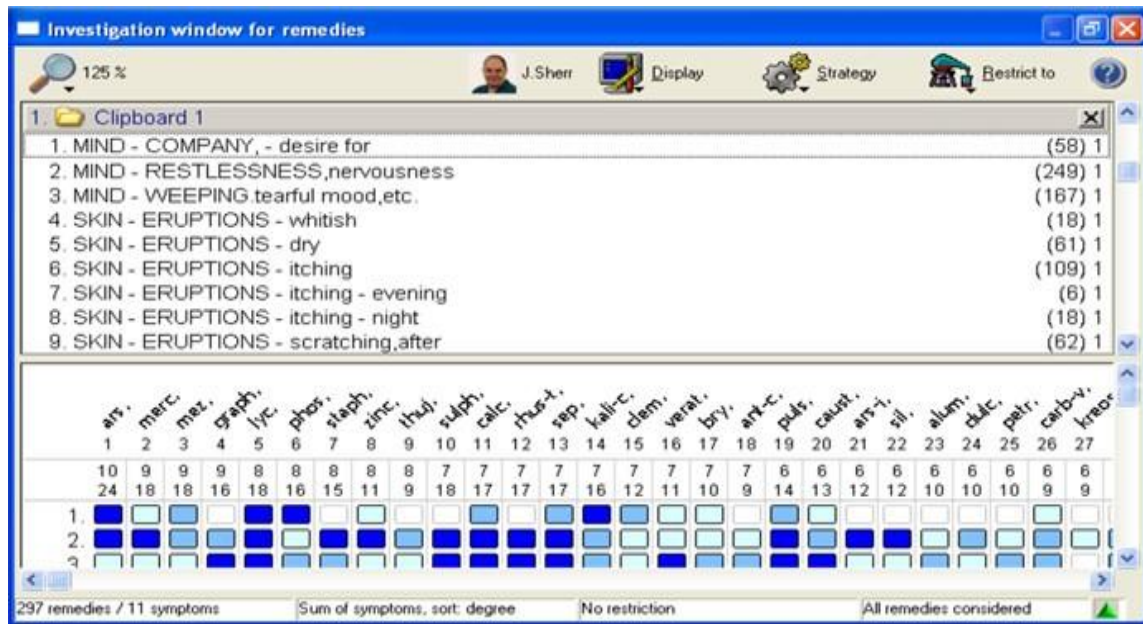


Figure 1. Repertorial Chart Picture

RESULT AND DISCUSSION

The patient with 10 years young boy presented with the complaints of Taenia Corporis with round scaly eruption, due to itching and scratching peeling of skin with shiny dry scales and after there with redness and everted margin. The provisional diagnosis is Taenia Corporis. The patient was treated with homoeopathic medicines orally for 2 months with weekly 3 dose administered as alternate morning. The figure of before and after eruption of the patient is show in figure 2.

Homoeopathy has a lot of medicines for treating the Taenia Corporis, after repertorisation⁴ medicines include Arsenicum Album, Merc Sol, Mezerium, Graphitis, Lycopodium, Phosphorus, Staphysagria, Zincum met, Thuja Occidentalis, Sulphur etc are come under the repertorisation result as shown in the table 2. From these similar remedies we should take the similimum for curing the case. So here by considering this the patient was treated with

GRAPHITIS 0/3 in weekly three doses administered in alternate morning. He got much improvement in it.

Philosophy of prescription:

This disease belonged to the Acute One Sided Disease with External in Nature and Internal in Origin. In the aphorism 171 in fifth edition it is clearly mentioned that in the case of non-venereal chronic disease, those, therefore, that arise from psora, we often require, in order to effect a cure, to give several antipsoric remedies in succession, every successive one being homoeopathically chosen in consonance with the group of symptoms remaining after the expiry of the action of the previous remedy (which may have been employed in a single dose or in several successive doses).⁵

Also in the aphorism 171 in sixth edition it is revealed that in non-venereal chronic disease, those, therefore, that arise from psora, we often require, in order to effect a cure, to give several antipsoric remedies in succession, every successive one being homoeopathically chosen in consonance with the group of symptoms remaining after completion of the action of the previous remedy.⁵

We choose LM Potency in this case because the selection of the similimum alone is not sufficient for a cure. The next step is choosing the exact potency and timely application of the dose. The potency and the dose also should be similar to the case. Here the individuality of the case decides the suitable remedy, potency and dose. New dynamization method diminished this period to “ one half, one quarter and even still less, not that much more rapid cure might be obtained ” aph:246. Frequent repetition is permissible for even long lasting remedies it can be repeated if and when necessary. Aph: 246FN

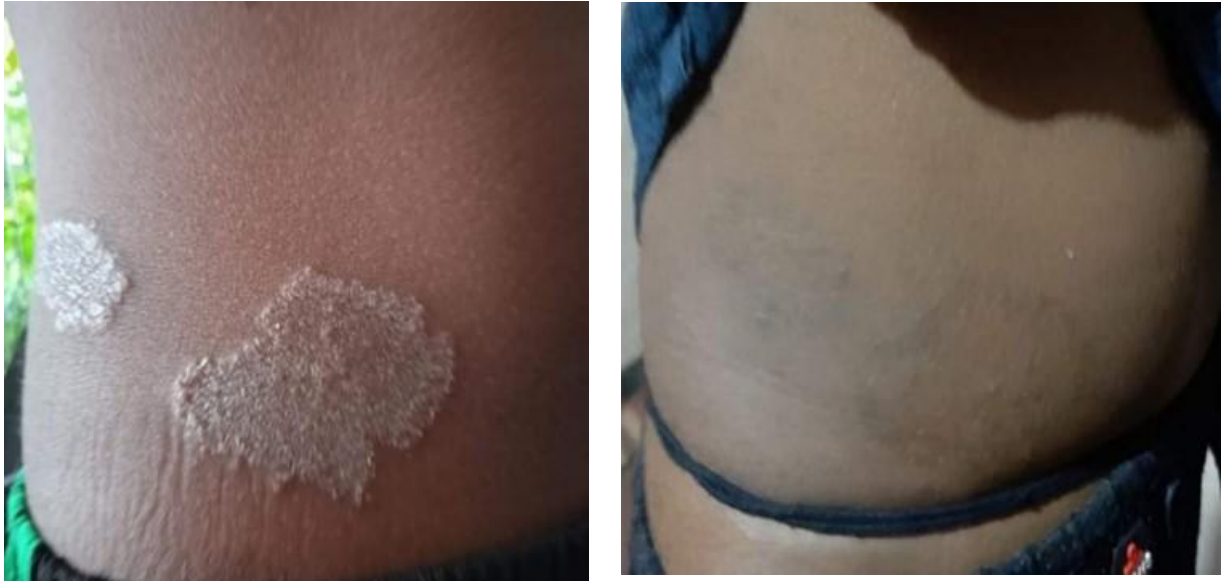

Figure: 2 Before and After Treatment

Table 3. Chart of Medicines Prescribed and Regular Follow-up

Date	Follow up	Medicine prescribed
01/06/2020 (First Prescription)	Skin complaint with eruptions, on the right side of abdomen with itching and scratching with peeling of skin. < night, > hot application.	GRAPHITIS 0/3 / 3 DOSE (ALT.M) for 1 week
09/06/2020	Skin complaint with eruptions, on the right side of abdomen feels better but itching and scratching with peeling of skin persists. < night	GRAPHITIS 0/3 / 3 DOSE (ALT.M) for 2 weeks
24/06/2020	Skin complaint with eruptions, on the right side of abdomen feels better and itching and scratching with peeling of skin slight better. Generals: good	GRAPHITIS 0/3 / 3 DOSE (ALT.M) for 2 weeks
09/07/2020	Skin complaint with eruptions, on the right side of abdomen feels better and itching and scratching with peeling of skin better. Peeling of skin relieved. Generals: good	GRAPHITIS 0/3 / 3 DOSE (ALT.M) for 1 week

18/07/2020	Skin complaint with eruptions, on the right side of abdomen feels better also diminished and itching and scratching with peeling of skin better. Peeling of skin relieved. Generals: Good	GRAPHITIS 0/3 / 3 DOSE (ALT.M) for 1 week
28/07/2020	Skin complaint with eruptions, on the right side of abdomen feels better also diminished and itching and scratching with peeling of skin better. Peeling of skin relieved. Generals: Good	GRAPHITIS 0/3 / 3 DOSE (ALT.M) for 2 weeks

CONCLUSION

Here in this case study it clearly understood about the action of Homoeopathic medicine in the case of skin complaint. Here we discuss about the case of Taenia Corporis with severe itching and eruption in the right side of abdomen. Case taken by the prescribed homoeopathic format and formed a totality. After repertorise the totality we select the GRAPHITIS in LM Potency for Taenia Corporis. Selection of remedy done according to the similimum. The patient got result while continuing the medicine for 2 months. Here LM Potency is used due to less aggravation. In the case of skin complaint there is chance for higher aggravation, so for controlling the aggravation and for the frequent repetition LM Potency is used in this case. Thus, homoeopathy plays a great role in acute diseases like Taenia Corporis and that was proved within evidences.

REFERENCES

- [1] Waheed Z., Ghosh R.K., Banerjee A. Tinea corporis resolute by homoeopathy: a case report. Int J Health Sci Res. 2021; 11(6): 135-139.
- [2] Mudenur, S., 2021. Tinea corporis and homoeopathic management: a case report. [online] www.homeobook.com. Available at: <<https://www.homeobook.com/tinea-corporis-and-homoeopathic-management-a-case-report/>> [Accessed 2 August 2021].
- [3] Pawshe, P., 2021. Tinea corporis -a case report. [online] www.homeobook.com. Available at: <<https://www.homeobook.com/tinea-corporis-a-case-report/>> [Accessed 2 August 2021].

- [4] Kent JT. Repertory of the homoeopathic materia medica. B. Jain Publishers, New Delhi; 1992.
- [5] Hahnemann Samuel. Organon of Medicine. Aphorism. 5th & 6th edition. New Delhi: B. Jain Publishers; 2005. p.126.