

# EFFICACY OF INDIVIDUALISED HOMOEOPATHIC TREATMENT FOR RESOLVING ATOPIC DERMATITIS: A CASE REPORT

**Arun S. Raj\* and M. Murugan**

*Department of Organon of Medicine and Homoeopathic Philosophy, Sarada Krishna Homoeopathic  
Medical College, Kulasekharam, Kanniyakumari District, Tamilnadu.*

## ABSTRACT

---

Eczema (atopic dermatitis) is a skin ailment that causes redness and itching. It's most frequent among children, although it can strike anyone at any age. Atopic dermatitis is a long-term (chronic) condition that flares up from time to time. It's possible that it'll be accompanied with asthma or hay fever. A cure for atopic dermatitis has yet to be discovered. Treatments and self-care techniques, on the other hand, can help to alleviate irritation and prevent future outbreaks. Avoiding harsh soaps, moisturising your skin regularly, and applying medicated lotions or ointments, for example, are all beneficial. The term atopic denotes a connection to allergies. While atopic dermatitis is not always caused by an allergic reaction, it is frequently linked to other allergic disorders: up to 60% of persons with atopic dermatitis eventually acquire asthma or hay fever (allergic rhinitis), and up to 30% have food allergies. Atopic dermatitis is frequently the start of a chain of allergic reactions known as the atopic march. Atopic dermatitis is usually the first symptom, followed by food allergies, then hay fever, and lastly asthma. Still, not everyone who has atopic dermatitis will continue through the atopic march, and not everyone who has one allergy condition will develop another.

---

**KEYWORDS:** Atopic Dermatitis, Case Report, Homoeopathy, Individualization, Sepia.

\* Corresponding Author E-mail: [arun.anjanaya@gmail.com](mailto:arun.anjanaya@gmail.com)

## INTRODUCTION

Atopic dermatitis is a prevalent, typically chronic skin condition that affects a huge portion of the world's population. Atopic dermatitis is a kind of allergic hypersensitivity linked to asthma, hay fever, and chronic dermatitis. <sup>(1)</sup> The condition is known to have a hereditary component, and it is

more common in affected families. The usual form and spread of the rash in a patient with a personal or family history of asthma and/or hay fever are among the criteria that allow a doctor to identify it. The term atopic comes from the Greek word atopic, which means "abnormal." The term dermatitis refers to skin inflammation. When referring to this ailment, many doctors and patients use the term eczema. It's also known as neurodermatitis. <sup>(2)</sup>

Atopic dermatitis is a highly common skin condition that is becoming more prevalent around the world. It affects both men and women equally and accounts for 10% to 20% of all dermatologist referrals (doctors who specialise in the care and treatment of skin diseases). Sixty-five percent of those affected develop symptoms in their first year of life, and ninety percent develop symptoms before the age of five. <sup>(3)</sup> Onset after the age of 30 is infrequent, and it usually happens when the skin has been exposed to extreme conditions. People who live in cities and in low-humidity regions appear to have a higher chance of acquiring atopic dermatitis. Approximately 10% of all newborns and early toddlers show signs of the condition. Approximately 60% of these infants have one or more atopic dermatitis symptoms even after they reach adulthood. This means that the disease affects more than 15 million people in the United States. <sup>(4)</sup>

## **MATERIALS AND METHODS**

### **Case Presentation**

Patient was a 38 years young lady in my clinics come with the complaints of skin eruptions especially in the abdomen – right side with two lesions for 1month. Lesions with blackish discoloration with in left dorsum of foot with itching. Itching leads to disfiguration of skin with bleeding and burning occurs. Itching aggravates in night especially when touching in cold application and ameliorates in hot application especially hot salt water external application. The patient complaints start before 2 years with itching and dryness of thumb, after that blackish discoloration with severe itching occurs. Took allopathic treatment but much relief didn't occur, only temporary amelioration in itching occurs. But reoccur vigorously. So patient stops the allopathic treatment and willing to take homoeopathic treatment.

Patients had a history of breathing difficulty before 5 years, now inhaler used continuously. Also patient had a history of chickenpox in childhood treated with homoeopathy. Physical generals

of the patient with increased thirst of hot water. Perspiration increased especially in frontal region. Sleep is decreased due to the continuous itching with profuse sweat over the whole body. Patient is mentally active with consolation ameliorates and worried about his studies. Very much restless and increased weeping disposition. Patient had aversion to covering and desires fanning.

The systemic examination of the patient reveals that skin of the patient with black circular patches over the dorsum of thumb, index finger and middle finger with much itching. Itching leading to the bleeding of affected area. Characteristic of lesion is black, dry and borders everted and thickened with itching and blood spots are present due to itching.

### **Homoeopathic Analysis**

Patient was treated as whole by considering similimum by constructing a symptom totality by considering his mental, physical and particular symptoms as shown in the table 1 and then repertorise the totality and make the rubrics as shown in table 2. After examining the Repertorial result first prescription is done. Repertorisation chart is shown in figure 1.

### **Homoeopathic Intervention**

The patient was treated and follows up with systemic manner by homoeopathic medicines that have been shown in the table 3 (follow up). The medicines were selected according to the present totality of symptoms. The periodic follow up were done through frequent intervals.

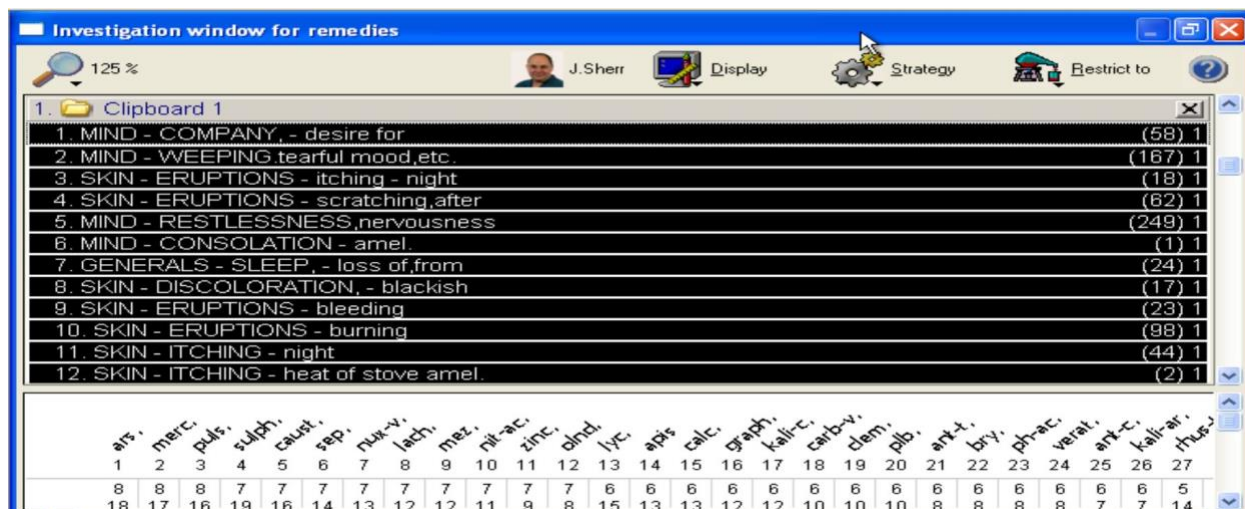
**Table 1. Symptoms Evaluation and Totality Based on First Day for the First Prescription**

<b>Mental</b>	<b>Physical</b>	<b>Particular</b>
Desires company	Thirst – Increased (hot water)	Blackish discoloration and
Restless about her complaints	Sleep - Decreased due to itching.	eruptions, on the left side of dorsum of foot.
Weeping disposition	Sweat – profuse over the frontal region	Itching leads to ulceration and blood flows out with burning sensation of foot.
Consolation amel:	Desire hot drinks	
	Desires fanning	

Aversion to covering.	Dry scales with everted margin , after scratching bleeding occurs  Itching  < night  > hot salt water application
-----------------------	---

**Table 2. Rearranging totality for the final selected remedy**

S. No	Repertorial totality	Repertorial result
1	Mind – company – desires for	Ars alb 18/8
2	Mind – weeping, tearful mood,	Merc sol 17/8
3	Mind – restlessness, nervousness	Puls 16/8
4	Mind – consolation – amel.	Sulph 19/7
5	Generals – sleep – loss of from	Caust 16/7
6	Skin eruptions – itching night	Sep 14/7
7	Skin eruptions – scratching – after	Nux vom 13/7
8	Skin – discoloration – blackish	Lach 12/7
9	Skin eruptions – bleeding	Mez 12/7
10	Skin – eruptions – burning	Nit acid 11/7
11	Skin –itching – night	
12	Skin – itching – heat off	



**Figure 1. Repertorial Chart Picture**

## RESULT AND DISCUSSION

The patient of 38 years young woman with Blackish discoloration and eruptions, on the left side of dorsum of foot. Itching leads to ulceration and blood flows out with burning sensation of foot. Dry scales with everted margin, after scratching bleeding occurs. The provisional diagnosis is Atopic Dermatitis. The patient was treated with homoeopathic medicines orally for 2 months with weekly 3 dose administered as alternate morning. The figure of before and after eruption of the patient is show in figure 2.

Homoeopathy has a lot of medicines for treating the Atopic Dermatitis, after repertorisation<sup>4</sup> medicines include Arsenicum Album, Merc Sol, Pulsatilla, Sulphur, Causticum Sepia, Nux Vomica, Lachesis, Mezerium, Nitric Acid etc are come under the repertorisation result as shown in the table 2. From these similar remedies we should take the similimum for curing the case. So here by considering this the patient was treated with SEPIA 0/3 in weekly three doses administered in alternate morning. She got much improvement in it.

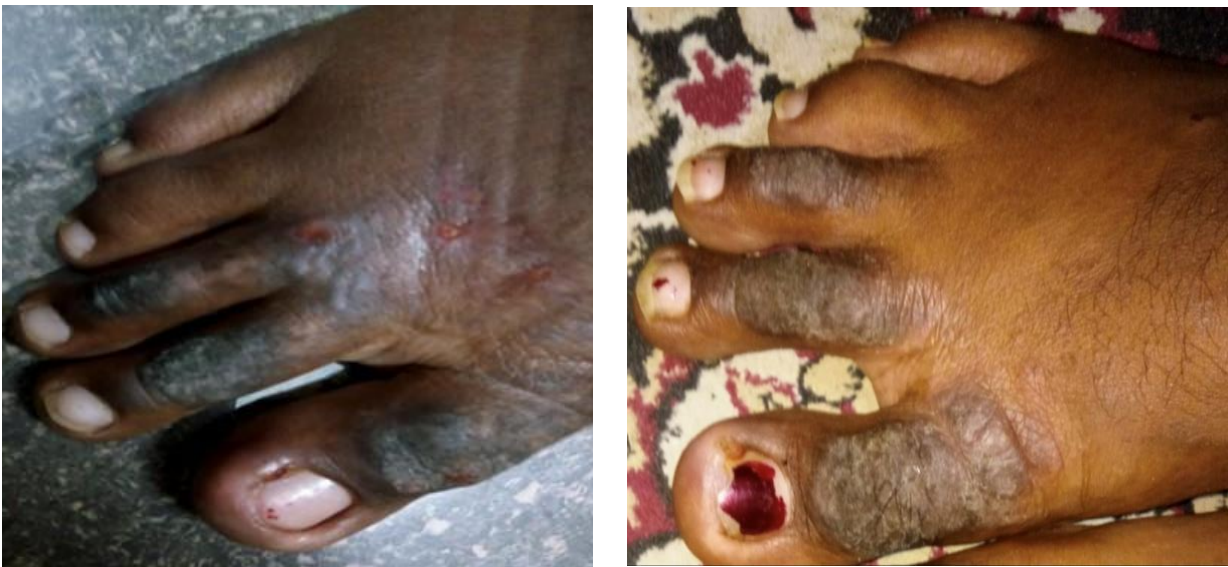### Philosophy of prescription:

This disease belonged to the Acute One Sided Disease with External in Nature and Internal in Origin. In the aphorism 171 in fifth edition it is clearly mentioned that in the case of non-venereal chronic disease, those, therefore, that arise from psora, we often require, in order to effect a cure, to give several antipsoric remedies in succession, every successive one being homoeopathically

chosen in consonance with the group of symptoms remaining after the expiry of the action of the previous remedy (which may have been employed in a single dose or in several successive doses).  
(4)

Also in the aphorism 171 in sixth edition it is revealed that in non-venereal chronic disease, those, therefore, that arise from psora, we often require, in order to effect a cure, to give several antipsoric remedies in succession, every successive one being homoeopathically chosen in consonance with the group of symptoms remaining after completion of the action of the previous remedy. (5)

We choose LM Potency in this case because the selection of the similimum alone is not sufficient for a cure. The next step is choosing the exact potency and timely application of the dose. The potency and the dose also should be similar to the case. Here the individuality of the case decides the suitable remedy, potency and dose. (6) New dynamization method diminished this period to “one half, one quarter and even still less, not that much more rapid cure might be obtained” aph:246. Frequent repetition is permissible for even long lasting remedies it can be repeated if and when necessary. Aph: 246FN



**Figure: 2 Before and After Treatment**

**Table 3. Chart of Medicines Prescribed and Regular Follow-up**

<b>Date</b>	<b>Follow up</b>	<b>Medicine Prescribed</b>
15/02/2021 (First Prescription)	Blackish discoloration and eruptions, on the left side of dorsum of foot. Itching leads to ulceration and blood flows out with burning sensation of foot. Dry scales with everted margin , after scratching bleeding occurs.	Sepia Officinalis 0/3 / 3 Doses (Alt.M) For 1 Week
23/02/2021	Blackish discoloration and eruptions, on the left side of dorsum of foot persist. Itching leads to ulceration and blood flows out with burning sensation of foot slightly decreases with burning sensation present. Dry scales with everted margin slightly amel.	Sepia Officinalis 0/3 / 3 Doses (Alt.M) For 1 Week
03/03/2021	Blackish discoloration and eruptions, on the left side of dorsum of foot slightly relieved. Itching leads to ulceration and blood flows out with burning sensation of foot slightly decreases with burning sensation present. Dry scales with everted margin slightly amel.	Sepia Officinalis 0/3 / 3 Doses (Alt.M) For 1 Week
14/03/2021	Blackish discoloration and eruptions, on the left side of dorsum of foot on the way to progress. Itching leads to ulceration and blood flows out with burning sensation of foot decreased with slight burning sensation. Dry scales with everted margin slightly amel.	Sepia Officinalis 0/3 / 3 Doses (Alt.M) For 1 Week
22/03/2021	Blackish discoloration and eruptions with dryness, on the left side of dorsum of foot ameliorated. Itching leads to ulceration and blood flows ameliorated	Sepia Officinalis 0/3 / 3 Doses (Alt.M) For 1 Week

03/04/2021	Blackish discoloration and eruptions, on the left side of dorsum of foot decreased. Itching leads to ulceration and blood flows out with burning sensation of foot relieved. Dry scales with everted margin ameliorated.	Sepia Officinalis 0/3 / 3 Doses (Alt.M) For 1 Week
------------	--	--

## CONCLUSION

Here in this case study it clearly understood about the action of Homoeopathic medicine in the case of skin complaint. Here we discuss about the case of Atopic Dermatitis of Blackish discoloration and eruptions, on the left side of dorsum of foot. Itching leads to ulceration and blood flows out with burning sensation of foot. Dry scales with everted margin, after scratching bleeding occurs. Case taken by the prescribed homoeopathic format and formed a totality. After repertorise the totality we select the SEPIA in LM Potency for Atopic Dermatitis. Selection of remedy done according to the similimum. The patient got result while continuing the medicine for 2 months. Here LM Potency is used due to less aggravation. In the case of skin complaint there is chance for higher aggravation, so for controlling the aggravation and for the frequent repetition LM Potency is used in this case. Thus, homoeopathy plays a great role in acute diseases like Atopic Dermatitis and that was proved within evidence.

## REFERENCES

1. Mayo clinics – disease conditions - conditions —atopic dermatitis - eczema . symptoms and its causes . syc 20353273. Health Sci Res. 2021; 11(6): 135-139.
2. The American Academy of Dermatology. Eczema types Atopic dermatitis over review. [www.aad.org.in](http://www.aad.org.in).
3. Kent JT. Repertory of the homoeopathic materia medica. B. Jain Publishers, New Delhi; 1992.
4. Hahnemann Samuel. Organon of Medicine. Aphorism. 5th & 6th edition. New Delhi: B. Jain Publishers; 2005. p.126.k



5. Close Stuart. The Genius of Homoeopathic Lectures and Essay on Homoeopathic Philosophy. Reprinted edition. New Delhi. B Jain publishers. Kuldeep. 2008-09. page no: 78-79.
6. Roberts HA. The principles and art of cure by Homoeopathy. 9<sup>th</sup> impression. New Delhi. B Jain publishers. Kuldeep Jain. 2010 page no: 162-167.
7. Allen HC. Keynotes and Characteristics with Comparisons of some of the Leading remedies of the Materia Medica with Bowel Nosodes. B. Jain Publishers; 2002.